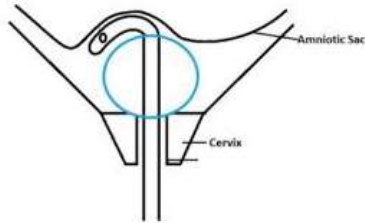


Foley Catheter for Cervical Ripening and Induction of Labour

R&R 2019- April 4, 2019

Jennifer Hughes-Large, PGY2 Obstetrics and Gynecology



Bronchu et al 2017. Obstetrical Cervical Ripening Device. Accessed Apr 1, 2019. <https://web.wpi.edu/Pubs/E-project/Available/E-project-042717-100851/unrestricted/FinalReport.pdf>

Evidence and indications

- Cervical ripening is typically recommended for a Bishop score < 6 with a vertex fetus
- Foley catheter is safe for use when other means of cervical ripening are contraindicated/ not recommended¹ (eg. Prostaglandins should not be used in previous C-section, asthma, glaucoma, suspected fetal compromise, unexplained vaginal bleeding, suspected CPD, grand multiparity – *William's Obstetrics 24th ed*)
- Similar induction-to-delivery time and C-section rate when Foley compared with prostaglandins, with decreased rate of uterine hyperstimulation with FHR changes²⁻⁷
- Shorter induction-to-delivery time if oxytocin induction is used concurrently with Foley placement, for both primips and multips⁸⁻¹⁰
- Foley volume can be 30-80 cc. Higher volumes may reduce induction-to-delivery time, but conflicting evidence^{11,12}
- May be some increased risk of intrapartum infection with Foley use, but controversial^{7,13,14}
- Outpatient Foley use is safe, cost-effective, well-tolerated, and may decrease rates of C-section compared with inpatient use¹⁵⁻¹⁸
- No role for Foley use after prelabour rupture of membranes (PROM) - may increase infection rate and no change in time to delivery^{19,20}
- Outcomes are not improved with double balloon catheters, and they are typically less well-tolerated²¹

What you need:

- Light and exam table with stirrups
- Sterile gloves
- Speculum (sterile) and lubricant
- Ring forceps (locking)
- 16F or 18F Foley catheter
- Sterile water/ saline (30-80 cc) in syringe
- Umbilical cord clamp
- Tape
- Fetal heart monitor
- Other nice-to-haves:
 - Condom with end cut off or equivalent
 - Pack for under sacrum
 - 2x2" sponges
 - Neonatal intubation stylette in case of performing blind insertion

Procedure steps

1. Confirm vertex presentation and perform cervical exam to ensure need for cervical ripening.
2. Set up all your materials. Grasp Foley with ring forceps ~1cm from end.
3. Position patient in dorsal lithotomy, preferably with feet in stirrups
4. Insert speculum to get a good view of the entire cervix. Take your time and reposition if needed to set yourself up for success.
5. Advance Foley into cervix until it is past internal os
6. Inflate with 30-80 cc sterile water/ saline
7. Tug gently to ensure correct position. No part of the balloon should be visible outside the cervix.
8. Remove speculum. If not 100% certain of placement, confirm with a cervical check. Balloon should be palpable deep to the external os with circumferential cervical tissue.
9. Apply cord clamp to open end. Tape to patient's leg to apply traction.
10. Monitor fetal heart rate for 60 minutes. Discharge home if FHR normal with discharge teaching to await call for induction.

Discharge instructions

Tug gently on Foley every couple of hours to see if it will fall out. If Foley falls out, throw it away and enjoy the rest of your evening. Do not come in to hospital until called for induction unless otherwise concerned.

Return to hospital if any of:

- Decreased fetal movement
- Period-like bleeding or clots (normal to have spotting after insertion and for the tube to fill with blood)
- Labour (after Foley has fallen out)
- Membrane rupture

Jen's rule for choosing a speculum in pregnancy

- Always use a Grave's (flared blades)!
- If no previous vaginal births and a normal BMI, choose a medium speculum
- Everyone else gets a large speculum

Troubleshooting tips

- "Verbal analgesia" to keep to patient as relaxed as possible.
- If unable to find cervix with speculum:
 - Put a pack under the sacrum
 - Remove speculum and confirm cervix location with cervical exam
- If unable to achieve an adequate view of the cervix due to redundant vaginal tissue, use a condom with the end cut off or equivalent to hold the vaginal walls open
- If the cervix is too deep in the vagina or being pushed away with attempted insertion:
 - Reposition the speculum
 - Consider a larger speculum

- Use a second sponge stick to grasp the anterior lip and apply gentle traction while advancing the Foley (do not use tenaculum in pregnancy due to increased vasculature)
- If unable to insert under direct visualization, attempt to insert blindly while performing a cervical exam:
 - Insert a neonatal intubation stylette into the Foley and bend to appropriate angle. This may require cutting a hole and inserting partway down the Foley so that the stylette tip reaches the tip of the Foley.
 - Guide Foley through external os using fingers and advance until past internal os.
 - Inflate balloon, confirm placement, and remove stylette
- If tube immediately fills with blood on insertion, remove and reinsert new Foley. You may have inserted too far hit the placenta. It's probably fine as long as bleeding settles and FHR tracing is normal.

References:

1. Kruit H, Wilkman H, Tekay A, Rahkonen L. Induction of labor by Foley catheter compared with spontaneous onset of labor after previous cesarean section : a cohort study. 2017;(April):787-792. doi:10.1038/jp.2017.50
2. Barda G, Herman HG, Sagiv R, et al. Foley catheter versus intravaginal prostaglandins E2 for cervical ripening in women at term with an unfavorable cervix : a randomized controlled trial. 2018;7058:3-8. doi:10.1080/14767058.2017.1355906
3. Mizrachi Y, Levy M, Bar J, Kovo M. Induction of labor in nulliparous women with unfavorable cervix : a comparison of Foley catheter and vaginal prostaglandin E 2. *Arch Gynecol Obs.* 2016;294:725-730. doi:10.1007/s00404-016-4026-9
4. Chen W, Xue J, Peprah MK, et al. A systematic review and network meta-analysis comparing the use of Foley catheters , misoprostol , and dinoprostone for cervical ripening in the induction of labour. 2016:346-354. doi:10.1111/1471-0528.13456
5. Wang H, Hong S, Liu Y, Duan Y, Yin H. Controlled-release dinoprostone insert versus Foley catheter for labor induction : a meta-analysis Controlled-release dinoprostone insert versus Foley catheter for labor induction : a meta-analysis. 2016;7058. doi:10.3109/14767058.2015.1086331
6. Eikelder MLG, Rengerink KO, Jozwiak M, et al. Induction of labour at term with oral misoprostol versus a Foley catheter (PROBAAT-II): a multicentre randomised controlled non-inferiority trial. *Lancet.* 2016;387:1619-1628. doi:10.1016/S0140-6736(16)00084-2
7. Zhu L, Zhang C, Cao F, et al. Intracervical Foley catheter balloon versus dinoprostone insert for induction cervical ripening.
8. Schoen CN, Grant G, Sciscione A, Hoffman MK. Intracervical Foley Catheter With and Without Oxytocin for Labor Induction. 2017;129(6):1046-1053. doi:10.1097/AOG.0000000000002032
9. Connolly KA, Kohari KS, Rekawek P, et al. SMFM Papers A randomized trial of Foley balloon induction of labor. *Am J Obstet Gynecol.* 2016;215(3):392.e1-392.e6. doi:10.1016/j.ajog.2016.03.034

10. Bauer AM, Lappen JR, Gecsi KS, Hackney DN. Cervical ripening balloon with and without oxytocin in. *Am J Obstet Gynecol*. 2018;219(3):294.e1-294.e6. doi:10.1016/j.ajog.2018.05.009
11. Manish P, Rathore S, Benjamin SJ, Abraham A, Jeyaseelan V, Mathews JE. A randomised controlled trial comparing 30 mL and 80 mL in Foley catheter for induction of labour after previous Caesarean section. 2013. doi:10.1177/0049475515626031
12. Schoen CN, Saccone G, Backley S, et al. Increased single-balloon Foley catheter volume for induction of labor and time to delivery : a systematic review and meta-analysis. 2018;97:1051-1060. doi:10.1111/aogs.13353
13. Gommers JSM, Diederer M, Wilkinson C, Turnbull D, Mol BWJ. European Journal of Obstetrics & Gynecology and Reproductive Biology Risk of maternal , fetal and neonatal complications associated with the use of the transcervical balloon catheter in induction of labour : A systematic review \$. *Eur J Obstet Gynecol*. 2017;218:73-84. doi:10.1016/j.ejogrb.2017.09.014
14. McMaster K, Sanchez-ramos L, Kaunitz AM. Evaluation of a Transcervical Foley Catheter as a Source of Infection A Systematic Review and Meta-analysis. 2015;126(3):539-551. doi:10.1097/AOG.0000000000001002
15. Policiano C, Pimenta M, Martins D, Clode N. European Journal of Obstetrics & Gynecology and Reproductive Biology Outpatient versus inpatient cervix priming with Foley catheter : A randomized trial. *Eur J Obstet Gynecol*. 2017;210:1-6. doi:10.1016/j.ejogrb.2016.11.026
16. Eikelder MLG, Baaren G Van, Rengerink KO, Jozwiak M, Leeuw JW De. Comparing induction of labour with oral misoprostol or Foley catheter at term : cost-effectiveness analysis of a randomised controlled multi-centre non-inferiority trial. 2018:375-383. doi:10.1111/1471-0528.14706
17. Gidaszewski B, Khajehei M, Mcgee T. Outpatient cervical ripening : discomfort / pain during speculum and Foley catheter insertion. *Midwifery*. 2018;67:57-63. doi:10.1016/j.midw.2018.09.012
18. Kruit H, Heikinheimo O, Ulander V-M, et al. Foley catheter induction of labor as an outpatient procedure. *J Perinatol*. 2016;36:618-622.
19. Mackeen AD, Durie DE, Lin M, et al. Foley Plus Oxytocin Compared With Oxytocin for Induction After Membrane Rupture. 2018;131(1):4-11. doi:10.1097/AOG.0000000000002374
20. Amorosa JMH, Stone J, Mph SHF, Booker W, Newland M, Bianco A. A randomized trial of Foley Bulb for Labor Induction in Premature Rupture of Membranes in Nulliparas (FLIP). *Am J Obstet Gynecol*. 2017;217(3):360.e1-360.e7. doi:10.1016/j.ajog.2017.04.038
21. Durie D, Lawal A, Zegelbone P. Other mechanical methods for pre-induction cervical ripening. 2015;39:444-449. doi:10.1053/j.semperi.2015.07.006