THE PRACTITIONER
LE PRATICIEN

The occasional ED ultrasound: focused assessment with sonography for trauma (FAST)

Kyle Sue, MD, CCFP
Department of Family Medicine, School of Medicine, Queen's University, Kingston, Ont.

Correspondence to: Kyle Sue; ksue@ualberta.ca

This article has been peer reviewed.

INTRODUCTION

The purpose of point-of-care ultrasonography in an emergency setting is to allow physicians to quickly rule in or rule out suspected life-threatening conditions, such as intra-abdominal hemorrhage, as the cause of a patient's abdominal pain or hypotension after sustaining trauma.[1] However, focused assessment with sonography for trauma (FAST) is only a preliminary test in the setting of trauma or hemodynamic instability. One cannot discharge a patient from the emergency department (ED) based solely on a negative FAST. If the patient is hemodynamically unstable and you suspect intra-abdominal hemorrhage, a negative FAST will probably not change your clinical suspicion.[2] Your primary goal for the occasional ultrasound in the rural ED is to assess it safely. The key to safety is not the ability to call a scan positive or negative, but knowing how to correlate your findings clinically. If you are not sure, continue management as if you had never done the scan at all.[3,4]

EQUIPMENT

- Any ultrasonography machine
- Low frequency (2–5 MHz) curvilinear probe (Fig. 1)
- Ultrasound gel or water-based lubricant

IMAGE GENERATION AND INTERPRETATION

Ultrasound scans are a cross-section of the area you are scanning, from superficial to deep (top of screen to bottom of screen). The convention is to hold the probe with the probe marker oriented toward the patient's head (cephalad). The probe marker corresponds to the side of the screen with the marker dot (conventionally on the top left side of the screen). Therefore, the left side of the screen will correspond to the cephalad direction. The probe is held longitudinally (parallel with the plane of the patient's body).[4]

FAST scans of the abdomen include the right upper quadrant (RUQ), left upper quadrant (LUQ) and suprapubic locations (Fig. 2). Though the subcostal cardiac view is considered a part of FAST, it will not be discussed in this article. All of the following scans are done with the patient lying supine.[4,5]

Right upper quadrant view

In the RUQ, important landmarks for FAST scans include the liver, kidney and diaphragm (Fig. 3). The hepatorenal space (Morison pouch) is the second lowest part of the supine abdomen, after the pelvis. However, any clinically significant intraperitoneal bleed will rapidly overflow from the pelvis into the RUQ via the right paracolic gutter. Blood in the LUQ tracks into the RUQ via the phrenicocolic ligament without needing to be diverted through the pelvis. In the RUQ, free fluid preferentially collects in the hepatorenal space, creating a solid black stripe between the 2 organs.[4] This view is able to detect intraperitoneal bleeding in 82%–95% of hypotensive patients with an

abdominal source of bleeding.[3,4,6] However, it must be noted that FAST can only reliably detect free fluid of more than 250–600 mL in adults.[4,7,8] If there is no solid black stripe between the liver and the kidney, then there is either no free fluid or less than the limit of detection.

Right upper quadrant scan

To perform the scan, hold the probe longitudinally, with the probe marker facing cephalad, at the level of the right costal margin in the anterior to mid-axillary line. While keeping the probe held in the same location on the patient's body, gently sweep anteriorly and posteriorly by tilting the probe. If you are unable to generate an image with anything recognizable, reposition the probe cephalad or caudad 1 or 2 rib spaces and try again. You can also try repositioning the probe more anteriorly or posteriorly until you can clearly identify the kidneys, which are posterior (retroperitoneal). It is prudent to visualize the entire hepatorenal interface, which involves being able to see the superior (diaphragmatic) edge of the liver and the liver tip, and sweeping the probe anteriorly and posteriorly until the kidney disappears from the screen in either direction. It is not necessary to be able to see the entire hepatorenal interface on the screen at any given time, but the parts that you are not able to see, you must visualize separately by repositioning the probe. The combination of images needs to show you the entire interface for you to call a scan negative.

Fig. 1. Low frequency (2–5 MHz) curvilinear probe.

However, if at any time you visualize free fluid, you can call the scan positive without having seen the entire interface.[4]

Left upper quadrant view

In the case of a splenic or left diaphragmatic injury, early detection of bleeding can be done with this view before the fluid overflows into the RUQ. Unfortunately, the LUQ view is more challenging than the RUQ view. This is because the spleen is smaller and more mobile than the liver, as well as higher and more posterior. Ribs can therefore easily be in the way of scanning.[4] The spleen is also close to the stomach, which can obscure the spleen or have its contents cause you to think that there is free fluid present.[4,6] Also, bowel gas can more easily impede scanning in this quadrant than in the RUQ.

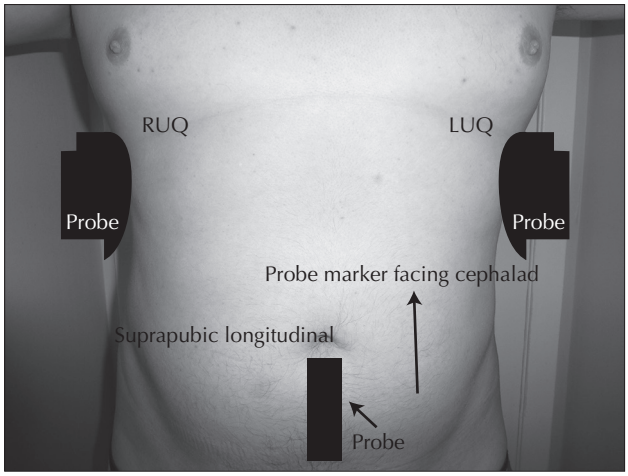

Fig. 2. Approximate positions of probes on patient's body for right upper quadrant (RUQ), left upper quadrant (LUQ) and suprapubic longitudinal views. The suprapubic transverse view is not shown.

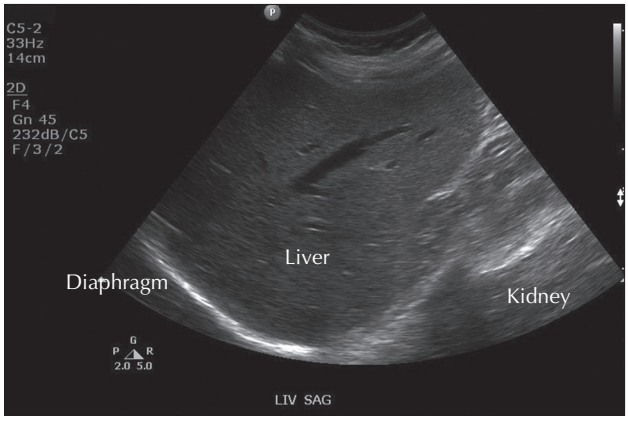

Fig. 3. Normal right upper quadrant view (on this still image, the entire hepatorenal interface is not visualized, so based on this image only, the scan is indeterminate, not negative).

Left upper quadrant scan

To do the scan, hold the probe longitudinally, with the probe marker facing cephalad, at the level of the left costal margin in the posterior axillary line (more posterior than for the RUQ view) with your hand almost resting on the bed. Because the spleen is more superior than the liver, you will likely need to position the probe more superiorly than on the right side. As with the RUQ scan, reposition the probe more cephalad or caudad, as needed, in order to visualize the spleen and the kidney. Sweep the probe anteriorly and posteriorly until the spleen disappears from the screen in either direction. On the LUQ view, fluid preferentially collects between the diaphragm (solid white curved line to the left of the spleen on the screen) and the kidney (Fig. 4). However, when there are large volumes of fluid, it can also collect in the splenorenal space. The diaphragm needs to be visualized to at least the 9 o'clock position on the screen to definitively call a negative scan.[4]

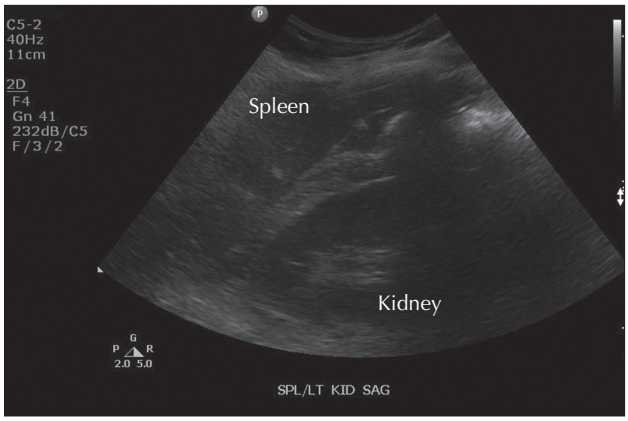

Fig. 4. Indeterminate left upper quadrant view (no diaphragm [thick white line] visualized left of the spleen on the screen).

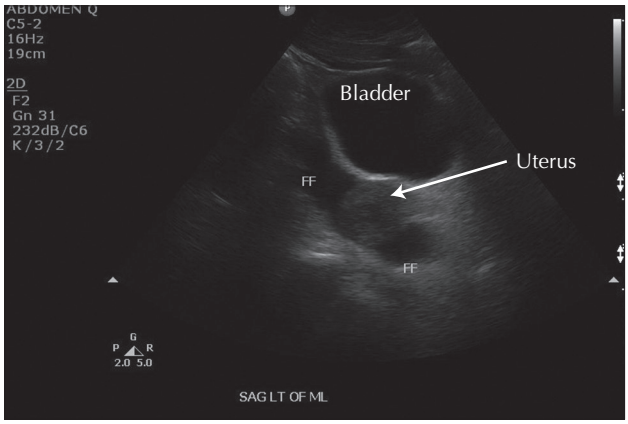

Fig. 5. Positive suprapubic longitudinal scan left of midline on patient (free fluid [FF] seen on both sides of the uterus deep to the bladder and also in a thin line deep to the uterus in the rectouterine space).

Suprapubic view

Minor bleeds can be easily detected with this view, especially if their origin is in the pelvis. In men, the area of interest with this view is the rectovesicular pouch. In women, the area of interest with this view is the rectouterine pouch (Douglas pouch).

Suprapubic scan

One can begin either with a transverse view or a longitudinal view. To do the longitudinal view, hold the probe longitudinally with the probe marker facing cephalad, placed in the abdominal midline between the umbilicus and the symphysis pubis, at a 90° angle to the skin. You may need to angle the probe 30° to 45° caudad (rather than completely upright at 90° to the skin) to visualize the bladder. The bladder appears as a fluid-filled organ (superficial black mass). In men, look for any black stripe posterior to the bladder (below the bladder on the screen). In women who have not had a hysterectomy, the uterus is a solid structure visualized immediately behind the bladder (Fig. 5). Look for any black stripe posterior to the uterus to identify free fluid.[4] A full bladder makes the suprapubic scan much easier to do, because urine (fluid) conducts ultrasound waves very well, giving a good "acoustic window." It is an option to instill 250 mL of fluid into the bladder via a Foley catheter to allow you to obtain a better picture, if you are having a difficult time getting a clear image with identifiable structures.[4,6] From the longitudinal view, immediately rotate the probe 90° counterclockwise to obtain the transverse view (probe marker facing to the patient's right)[4] (Fig. 6).

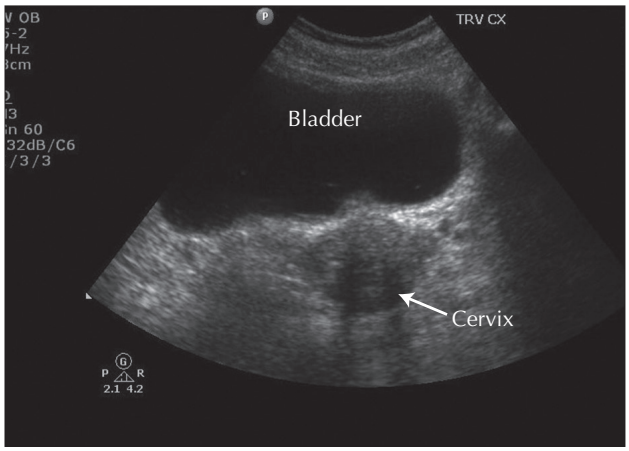

Fig. 6. Normal suprapubic transverse view (no fluid seen deep to the bladder on either side of the uterus/cervix, and no fluid seen deep to the uterus/cervix).

CASES

Case 1

A 32-year-old man is involved in a high-speed snowmobile rollover on the local mountain. He is brought in by paramedics 1 hour after the accident. He is alert and oriented, with a Glasgow Coma Scale score of 15. His blood pressure is 130/80 mm Hg, heart rate is 110 beats/min, respiratory rate is 16 breaths/min and blood oxygen saturation as determined by pulse oximetry (SpO_2) is 97% on room air. He reports abdominal pain. As an adjunct to your primary survey, you reach for the bedside ultrasonography machine to conduct a FAST scan. Your findings are shown in Figure 7.

In this case, the patient remains stable, so you can safely arrange computed tomography (CT), if available, to assess where the patient is bleeding from and whether he will need surgical management.[2] If CT is not available, ensure the patient is given intravenous fluids and possibly packed red blood cells before transfer to your referral hospital with surgical capabilities.[7]

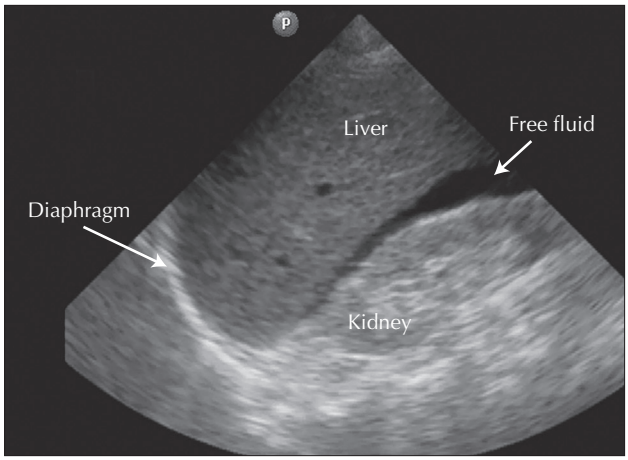

Fig. 7. Positive right upper quadrant view (free fluid in hepatorenal space).

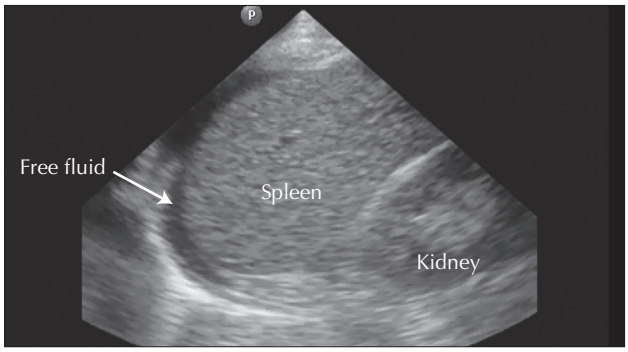

Fig. 8. Positive left upper quadrant view (free fluid between spleen and diaphragm).

Case 2

An 80-year-old woman was seen falling down a 10-m flight of stairs, and was brought into your rural ED by family members within 15 minutes of the accident. On arrival, she is diaphoretic and visibly short of breath. She appears confused and is unable to respond to any of your questions. Her blood pressure is 80/60 mm Hg, heart rate is 130 beats/min, respiratory rate is 30 breaths/min and SpO_2 is 88% on room air. While doing your primary survey and initiating appropriate resuscitation, you reach for your ultrasound probe to do a FAST scan. Your findings are shown in Figure 8.

In this case, your FAST scan finds free fluid from a hemorrhage secondary to a splenic injury (not visible in Fig. 8). Although you have found this, you must still rule out other potential causes of shock after trauma, such as tension pneumothorax or cardiac tamponade, which should become clear on physical examination or further ultrasonography. For high-impact traumas, there could be more than one contributor to shock.[4]

This patient needs surgery as soon as possible.[2]

Case 3

A 40-year-old male pedestrian crossing an unlit rural intersection at night is hit by a drunk driver at 30 km/h. He is tossed 50 m into a cornfield. Paramedics bring him into your ED, alive but unconscious. His blood pressure is 80/60 mm Hg, heart rate is 60 beats/min, respiratory rate is 25 breaths/min, SpO_2 is 88% on 15 L of supplemental oxygen by nonrebreather. While doing your primary survey and initiating appropriate resuscitation, you perform a FAST scan, which is negative for free fluid (Figs. 9 and 10). Given the hypotension and bradycardia, he is likely to have neurogenic shock. However, given the mechanism of injury, one cannot rule out an intraperitoneal bleed that has simply not yet reached the volume required for detection. If his condition stabilizes, it would be appropriate to do another FAST scan to see if there has been any interval change.[2,4]

Case 4

A 15-year-old boy falls off his skateboard while doing a jump at the local skate park. He falls 5 m onto concrete. In addition to multiple broken bones in his extremities, he is actively vomiting and complains of abdominal pain. His blood pressure in the ED 1 hour after the accident is 120/80 mm Hg, heart rate is 95 beats/min, respiratory rate is 18 breaths/min and

SpO_2 is 97% on room air. As part of your primary survey, you conduct a FAST scan to see if there is intraperitoneal bleeding as a cause of his abdominal pain. Your FAST scan is negative.

Thirty minutes later, he reports that his abdominal pain is worsening. A repeat FAST scan is negative. Two hours later, his blood pressure drops to 90/60 mm Hg and his heart rate is 110 beats/min. This time, the FAST scan is positive for free fluid (Fig. 11). A CT scan later identifies a subtle splenic laceration.

This case demonstrates the utility of doing serial FAST scans for a patient who is clinically stable but whom you highly suspect could have an intra-abdominal bleed.[2,4,6,7,9]

CAVEATS

False positives

- Perinephric fat can be easily confused with free fluid. However, fat does not conduct ultrasound waves to the same degree as fluid. Therefore, fat will appear more echogenic (lighter) and more blurry than the dark uniform line one expects with free fluid. If you are unsure, compare your image to the other side of the abdomen. If the same image appears on both sides, it can be reassuring that this is fat rather than fluid.[4,6]
- Ascites is a form of intra-abdominal free fluid. Therefore, for a patient who has pre-existing ascites, one cannot use a FAST scan to rule out an intra-abdominal hemorrhage. Peritoneal dialysis fluid and urine from a ruptured bladder will also look identical to free fluid.[4,6]
- Physiologic free fluid is often present in a small amount in women. Therefore, a small volume of fluid in the pelvis can be normal, though usually less than what a FAST scan can detect. Clinical correlation is necessary.[4,6]
- Intraluminal bowel and intragastric fluid can both mimic free fluid. However, fluid in the bowel or stomach should appear within loops of bowel or the stomach, and can usually be

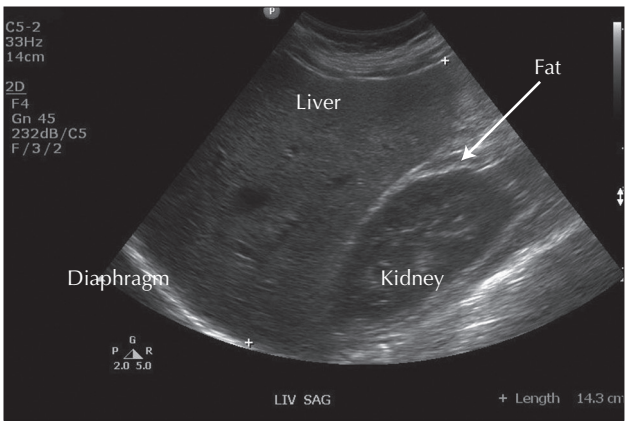

Fig. 9. Right upper quadrant view (no free fluid in this still image; can be called negative if entire interface shows no free fluid).

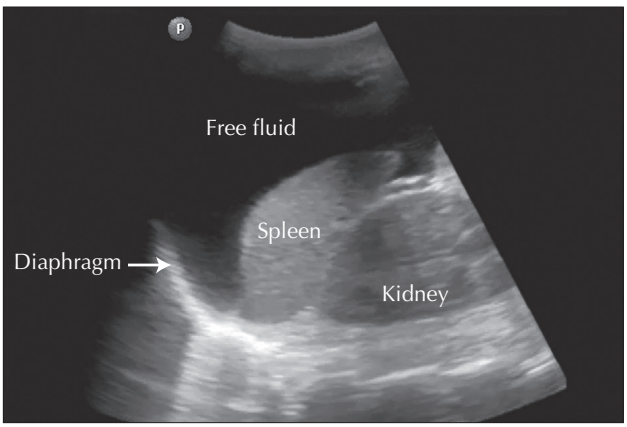

Fig. 11. Positive left upper quadrant view (very large volume of free fluid between the diaphragm and spleen).

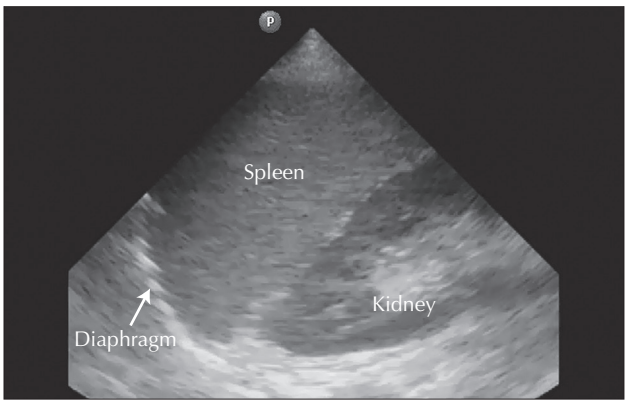

Fig. 10. Left upper quadrant view (no free fluid in this still image; can be called negative if entire interface shows no free fluid).

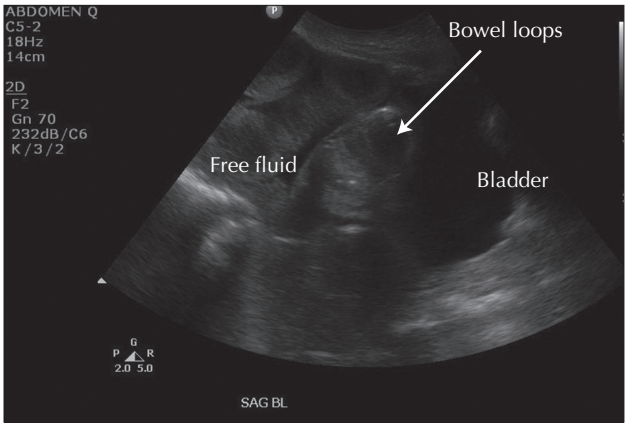

Fig. 12. Suprapubic longitudinal view showing free fluid superior to the bladder and around loops of bowel.

identified on the screen (Fig. 12). The fluid should appear contained within a structure rather than free flowing within the abdomen. Look also for peristalsis, which might be the biggest giveaway. Also, keep in mind the 3 locations where free fluid preferentially flows in the abdomen. If the fluid you see is not in any of those 3 locations, chances are low that it is free fluid.[4,6] The prostate in men can sometimes appear like free fluid. However, similar to perinephric fat, it is more echogenic (brighter) than the nonechogenic (dark) free fluid, and will appear to be confined to a structure shaped like the prostate. If unsure, one can simultaneously do a digital rectal examination. If the area in question moves on the screen when the prostate is palpated, it is the prostate.[4]

- The gallbladder or any cysts can be confused as free fluid. However, the fluid within these structures will be neatly confined to an oval or round shape with echogenic walls[4] (Fig. 13). Blood vessels (e.g., hepatic vessels or inferior vena cava) or biliary ducts can be mistaken for free fluid (Fig. 13). Again, these structures will appear as fluid neatly contained within a tubular structure.[4]

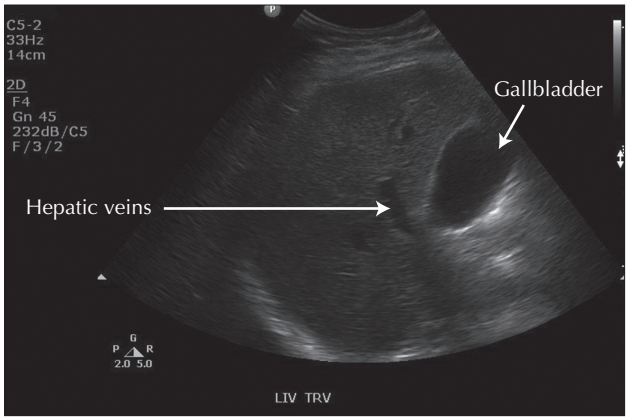

Fig. 13. Right upper quadrant view showing the gallbladder and hepatic veins, which can be mistaken for free fluid.

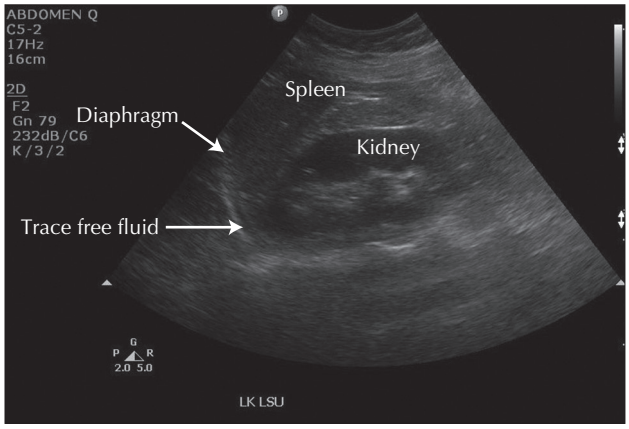

Fig. 14. Left upper quadrant view showing trace free fluid between the diaphragm and spleen.

False negatives

- Adhesions can constrict free fluid to a localized area that the FAST scan fails to pick up, because the fluid never reaches the most dependent locations in the abdomen.[4]
- Delayed presentations can be problematic.[2,4,6,7,9] Case 4 is one such example. Another possibility is that after 12–24 hours posttrauma, the blood may have clotted. Clotted blood will appear as a more echogenic area (whiter/brighter), which can be easily missed.[4,6] However, if the patient is still alive 24 hours posttrauma with an intra-abdominal hemorrhage, they probably do not require emergency surgery.[4]
- Moving one's hands too quickly while sweeping can easily cause the clinician to miss subtle fluid collections without realizing[4] (Fig. 14).

TROUBLESHOOTING

- Place the patient in a Trendelenburg position of 5° for 15–20 minutes for both RUQ and LUQ views. This can help bring small amounts of fluid into the dependent locations in the upper quadrants. Conversely, the reverse Trendelenburg position will help bring fluid into the most dependent part of the pelvis, decreasing the amount of free fluid needed for reliable detection by 50%.[4]

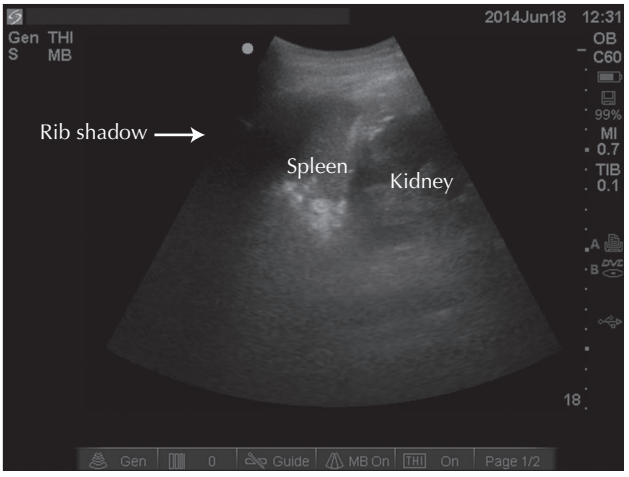

Fig. 15. Left upper quadrant view showing a rib shadow obscuring the diaphragm and part of the spleen.

- Start your scan at maximal depth on the screen, and decrease the depth as needed. This ensures you do not miss anything that is cut off on the screen at low depth.
- Angle the probe around 30° to get rib shadows out of the way, if the rib shadows are preventing you from seeing the landmarks and interfaces you are seeking[4] (Fig. 15). Have the patient take a deep breath and hold. This can sometimes shift your landmarks into places where they are not obscured by bowel gas or rib shadows.[4]
- Rescan or perform serial scanning (see case 4).
- Adjust the gain if your image is too dark or too bright for you to differentiate structures or clearly visualize what you are seeking.[4]

Acknowledgement: The author thanks Dr. Richard McCrea of Saskatchewan for generously exposing his abdomen for Figure 2 of this publication.

Competing interests: None declared.

REFERENCES

1. Tso P, Rodriguez A, Cooper C, et al. Sonography in blunt abdominal trauma: a preliminary progress report. *J Trauma* 1992;33:39-43; discussion 43-4.
2. Boulanger BR, et al. Prospective evidence of the superiority of a sonography-based algorithm in the assessment of blunt abdominal injury. *J Trauma* 1999;47:632-7.
3. Stengel D, et al. Emergency ultrasound-based algorithms for diagnosing blunt abdominal trauma [review]. *Cochrane Database Syst Rev* 2013; (7):CD004446 10.1002/14651858.CD004446.pub3.
4. Wiss R, Socransky S. *Point-of-care ultrasound for emergency physicians: "the EDE book."* 2012; 73-100.
5. Boulanger BR, et al. Emergent abdominal sonography as a screening test in a new diagnostic algorithm for blunt trauma. *J Trauma* 1996;40:867-74.
6. Tsui CL, Fung HT, Chung KL, et al. Focused abdominal sonography for trauma in the emergency department for blunt abdominal trauma. *Int J Emerg Med.* 2008;1:183-7.
7. Smith ZA, et al. FAST scanning in the developing world emergency department. *S Afr Med J* 2010;100:105-8.
8. Branney SW, Wolfe RE, Moore EE, et al. Quantitative sensitivity of ultrasound in detecting free intraperitoneal fluid. *J Trauma* 1995;39:375-80.
9. Sherbourne CD, Shanmuganathan K, Mirvis SE, et al. Visceral injury without hemoperitoneum: a limitation of screening abdominal sonography for trauma. *Emerg Radiol* 1997;4:349-54.