



THE PRACTITIONER LE PRACTICIEN

The occasional eye removal for corneal transplantation

William McCready,
MD

Professor of Medicine, Associate
Dean, Faculty Affairs,
Northern Ontario School of
Medicine, Thunder Bay, Ont.

Correspondence to:
Dr. William McCready,
Northern Ontario School of
Medicine, ATAC Building,
6th floor, 955 Oliver Rd.,
Thunder Bay ON P7B 5E1;
William.McCready@
NorMed.ca

This article has been peer
reviewed.

INTRODUCTION

Organ retrieval provides a service to both recipients and donor families. Many patients and their families wish to donate organs at the time of death and eye donation is rarely contraindicated. Corneal transplantation is a commonly performed procedure in Canada and is done either to restore sight or eye integrity. Corneal scarring, degeneration and dystrophy, keratoconus and keratoglobus are conditions that may require corneal transplantation. In 2006, 7065 eyes were donated and 2447 corneal transplantation procedures were performed in Canada.¹ More than 40 000 corneal transplantations are performed annually in the United States.² There is always a demand for donor corneas, and Canadian corneal transplantation surgeons report having an average waiting list of 50 patients and performing 33 procedures per year.³ The cornea is an avascular structure, thus allowing postmortem eye retrieval, which is a relatively simple procedure. Donor enucleation presents a unique opportunity for Canada's rural physicians to become involved in this important process.

Eyes should be removed within 12 hours for donors who have been refrigerated or within 4 hours if the donor has been kept at room temperature.

Following retrieval, the eyes are stored in a container of ice and must be received by the eye bank within 12 hours. Thus it is important to ensure that there is a local mechanism in place which allows these timelines to be met. In Ontario, the eye bank will pick up donated eyes at the Toronto airport. The list of resources at the end

of this article provides contact information that could be used to set up logistics for a local program, and the eye bank would be able to supply containers and insulated vessels for transport purposes.

INDICATIONS

Donors may be from 2 to 100 years of age.

CONTRAINDICATIONS

- hepatitis B or C
- HIV
- Creutzfeldt–Jakob disease
- septicemia
- encephalitis
- Reye syndrome
- rabies
- congenital rubella syndrome
- endocarditis
- Alzheimer disease
- multiple sclerosis
- amyotrophic lateral sclerosis
- intravenous drug use or other risky social behaviour

EQUIPMENT

The following equipment is required (Fig. 1):

- eyelid retractor;
- small-toothed forceps;
- muscle hook;
- sharp dissecting scissors;
- large curved scissors (non-pointed);
- 4 × 4 gauze;
- Kelly clamp.

These items can be obtained from any instrument supply company for about \$350. They may also be supplied by the Eye Bank of Canada.

PROCEDURE

Before proceeding, check that the consent form has been signed.

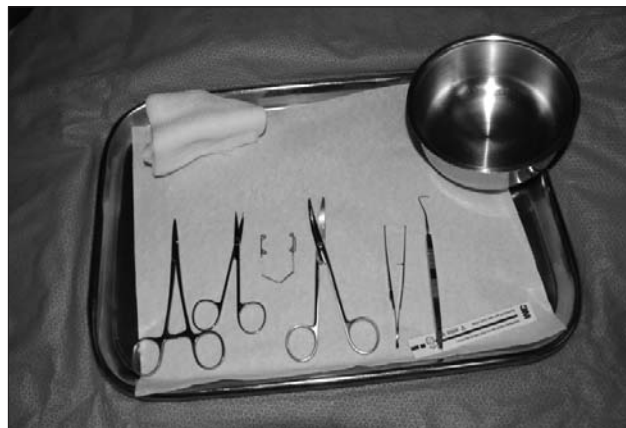

Fig. 1. Equipment required for enucleation.

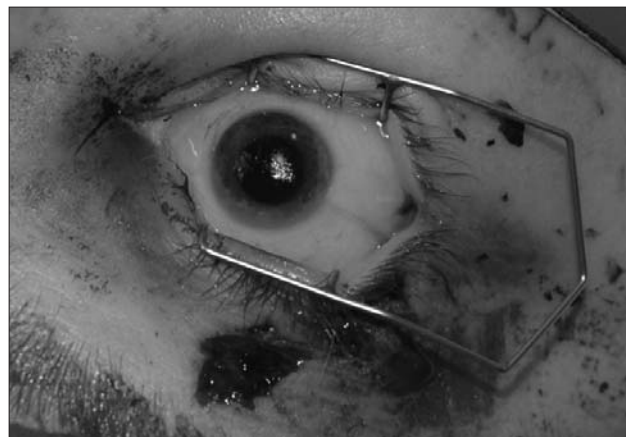


Fig. 2. Eyelid retractor in place.



Fig. 3. Incision of the conjunctiva.

1. The most convenient place to stand is behind the head.
2. Place the eyelid retractor to allow access to the eye (Fig. 2).
3. Using the toothed forceps pick up the conjunctiva just outside the margin of the iris (Fig. 3) and with the sharp dissecting scissors make a circular incision circumferentially around the iris.
4. Use the muscle hook to snare either the lateral or medial rectus muscle. This can be best achieved by running the hook along the surface of the globe deeper than the anticipated insertion point of the muscle and then sliding it back until the muscle body is hooked. If you are right-handed it is more convenient to hook the medial rectus of the right eye and the lateral rectus of the left eye, as this will allow easier use of the dominant hand when dividing the optic nerve.
5. Place the clamp on the muscle (Fig. 4) and divide the muscle distal to the clamp with the sharp scissors. This will result in the clamp being attached to the divided muscle and will allow you to use it to control movement of the globe.

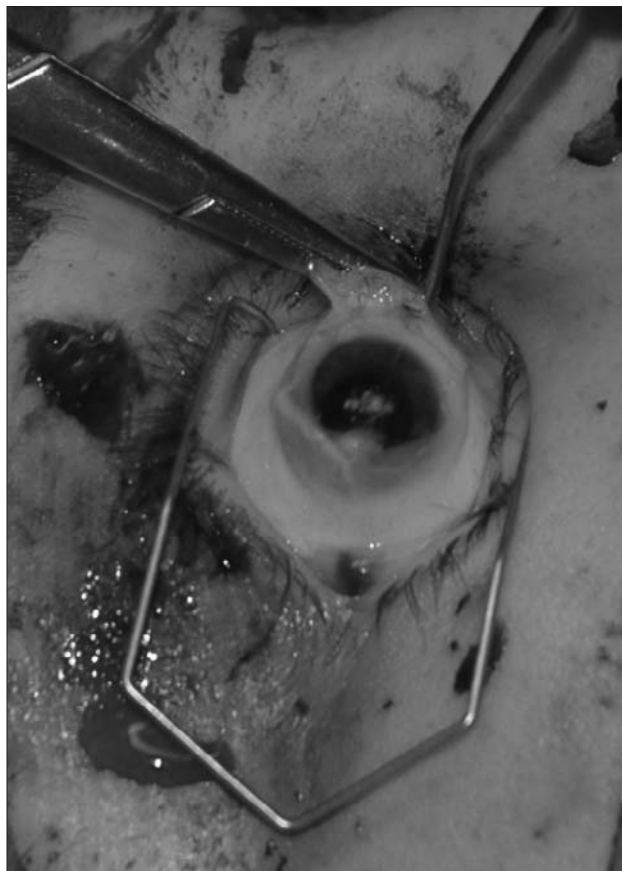


Fig. 4. Clamp in place on the rectus muscle.

6. Next use the muscle hook to snare the superior, inferior, and lateral or medial recti muscles and divide them with the sharp scissors. Often the inferior and superior oblique muscles are so

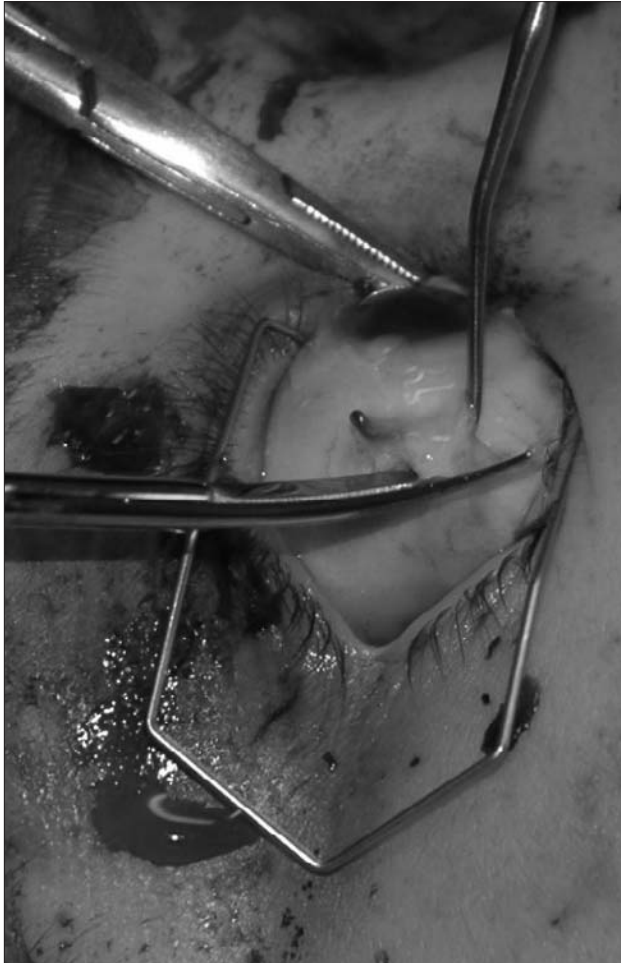

Fig. 5. Division of the lateral rectus muscle.

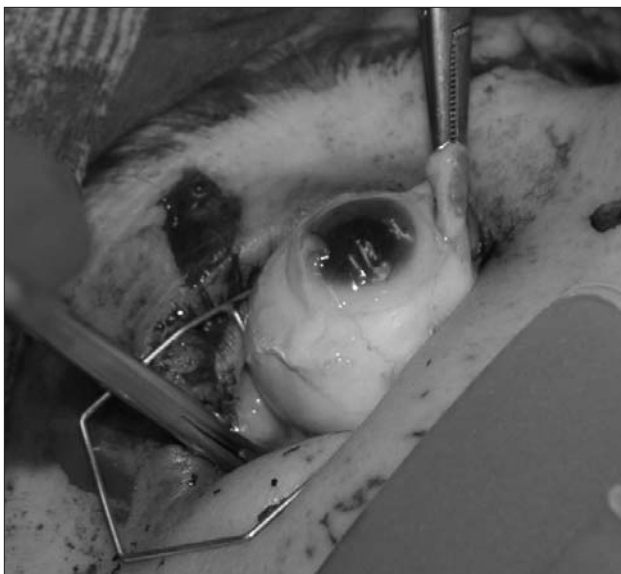

Fig. 6. Division of the optic nerve.

small as to be unidentifiable but failure to identify these muscles will not interfere with the procedure (Fig. 5). Once the extraocular muscles have been divided the optic nerve must be divided. This part of the procedure is critical as it is the only time when it is possible to penetrate the globe, hence releasing vitreous humour and collapsing the cornea.

7. Take the curved scissors and slide them behind the eye on the side opposite to the clamp. Open the scissors and push back against the posterior wall of the orbit while pulling up slightly with the clamp attached to the rectus muscle. Divide the optic nerve, which is quite tough and gritty feeling. It may be necessary to make several attempts before the nerve falls between the 2 blades of the scissors (Fig. 6).
8. The eye should now lift free of the orbit although it may be necessary to trim some extraneous tissue with the scissors to free it entirely.
9. The eye must now be placed in the container supplied by the eye bank. First soak the cotton in the bottom with sterile saline. This can conveniently be done by pouring in a generous amount of saline and then pouring off the excess. Ensure that the rolled gauze in the bottom of the container forms a ring around the gauze to provide some support for the eye. The eye should be placed cornea up in the container, which is then closed and placed on ice in the container provided (Fig. 7).
10. Roll up a single piece of gauze 4×4 by folding it lengthwise in 4, then rolling it up (Fig. 8). Push this gauze into the empty orbit and close the eyelids. It may take several attempts to close the lids over the gauze but this will help to

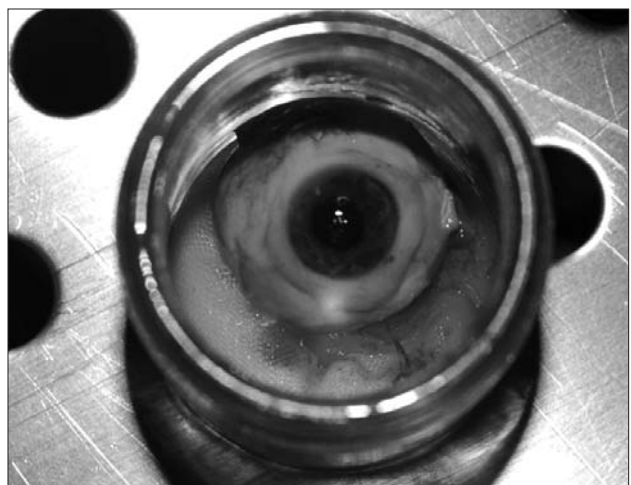


Fig. 7. Eye placed in transport container.

prevent collapse of the upper lids making the funeral director's work easier (Fig. 9). Try to ensure the eyelashes are not pushed back into the eye socket. Do not be tempted to use more than a single piece of gauze as it will prove impossible to close the lids under this circumstance.

11. Repeat the procedure for the second eye, remembering to start the process with the appropriate rectus muscle to allow use of the dominant hand to divide the optic nerve.
12. The eye bank will require 10 mL of clotted blood for HIV and hepatitis B serology. Depending on the time since death this can be something of a challenge but can usually be obtained from either the femoral or internal jugular vein.
13. A form with the donor demographics, brief medical history and enucleating physician information must be filled in and sent with the eyes to the eye bank.

Many rural physicians work in settings that make it difficult for them and their patients to participate in organ donation. However, all but the most isolated can participate in eye bank programs. Although removal of donor eyes may seem an intrusion into an already busy clinical day, families are generally most grateful for the opportunity to have their relatives' last wishes fulfilled, and such a donation can restore sight for up to 2 people.

Corneal transplantation is usually either sight preserving or restoring and is truly appreciated by recipients, as illustrated by this quote from Dr. Bill Ulakovic (personal communication, 2007):

As an optometrist in private practice for 20 years I have seen several patients that have undergone successful corneal transplants. Although a number of these patients have received a

corneal transplant as a result of a corneal injury or corneal dystrophy, the largest group of patients that I see is healthy young adults with keratoconus. Fortunately, most patients with keratoconus can be fitted with rigid gas-permeable contact lenses and achieve excellent visual acuity. However, if their disease progresses and they are unable to tolerate wearing contact lenses they have no other option for visual rehabilitation but to have their name placed on the waiting list for a corneal graft. These patients, many of whom are in the prime of their educational years or beginning a career, are often unable to carry on with their daily activities. As their vision deteriorates they wait indefinitely for a cornea to be donated. Receiving a corneal transplant truly does give these patients the gift of sight that so many of us take for granted.

USEFUL RESOURCES

- Eye Bank of Canada, Ontario Division, Toronto, Ont.; 416 480-7465; www.eyebank.utoronto.ca; eye.bank@utoronto.ca
- Eye Bank of British Columbia, Vancouver, BC; 604 875-4567; www.eyebankofbc.ca; eyebankofbc@vch.ca
- Lions Eye Bank (Alberta) Society, Calgary, Alta.; 403 943-3406; www.act4sight.com; info@act4sight.com
- Lions Eye Bank of Saskatchewan, Saskatoon, Sask.; 306 655-8002; www.medicine.usask.ca/ophthalmology/lions-eye-bank
- Lions Eye Bank of Manitoba and Northwest Ontario, Winnipeg, Man.; 204 788-8419; www.eyebankmanitoba.com; eyebank@miserc.winnipeg.mb.ca
- Quebec Eye Bank, Montréal, Que.; 514 252-3886
- New Brunswick Eye Bank, Saint John, NB; 506 632-5541
- Regional Tissue Bank, Halifax, NS; 902 473-4171
- Organ Procurement and Exchange Program of Newfoundland and Labrador, St. John's, NL; 709 737-6600

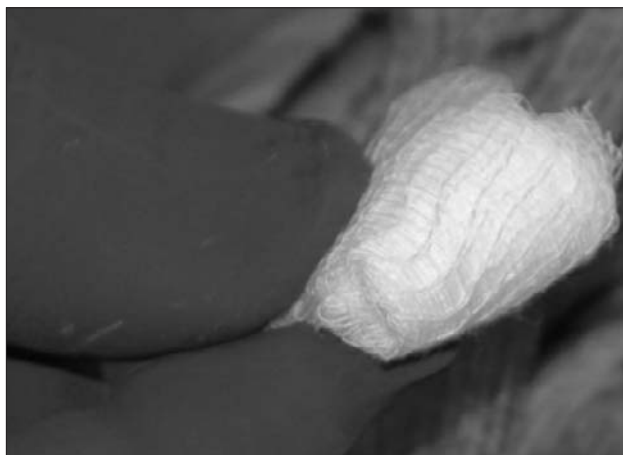


Fig. 8. Rolled up gauze.

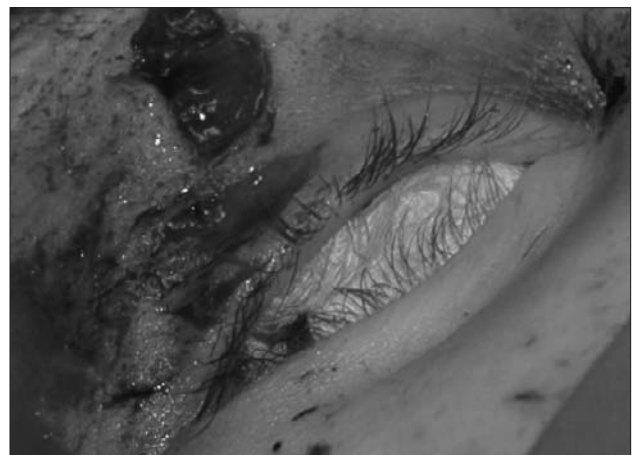


Fig. 9. Orbit packed with gauze.

- Eye Bank Association of America, Washington, DC; 202 775-4999; www.restoresight.org; info@restoresight.org

Acknowledgements: With thanks to Dr. Jan Czarnecki (ophthalmology) for teaching me the procedure and Dr. Bill Ulakovic (optometry) for the clinical context comment.

Competing interests: None declared.

REFERENCES

1. Eye Bank of Canada [website]. Available: www.eyebank.utoronto.ca (accessed 2008 Sept 30).
2. Eye Bank Association of America [website] Available: www.restoresight.org/general/anniversary.htm (accessed 2008 Sept 25).
3. Cao KY, Dorrepaal SJ, Seamone C, et al. Demographics of corneal transplantation in Canada in 2004. *Can J Ophthalmol* 2006; 41:688–92.

Country Cardiograms

Have you encountered a challenging ECG lately?

In most issues of *CJRM* an ECG is presented and questions are asked.

On another page, the case is discussed and the answer is provided.

Please submit cases, including a copy of the ECG, to Suzanne Kingsmill, Managing Editor, *CJRM*, P.O. Box 4, Station R, Toronto ON M4G 3Z3; cjrm@lino.com

Cardiogrammes ruraux

Avez-vous eu à décrypter un ECG particulièrement difficile récemment?

Dans la plupart des numéros du *JCMR*, nous présentons un ECG assorti de questions.

Les réponses et une discussion du cas sont affichées sur une autre page.

Veuillez présenter les cas, accompagnés d'une copy de l'ECG, à Suzanne Kingsmill, rédactrice administrative, *JCMR*, C. P. 4, succ. R, Toronto (Ontario) M4G 3Z3; cjrm@lino.com