



THE PRACTITIONER LE PRATICIEN

Country cardiograms case 25

*Keith MacLellan, MD
Shawville, Que.*

*Correspondence to:
Dr. Keith MacLellan,
PO Box 609, Shawville
QC J0X2Y0*

*This article has been peer
reviewed.*

A 19-year-old man comes to your emergency department very late one Friday night. He is not from your area, but has been drinking with some buddies at a local tavern. He is feeling weak and complains of palpitations. Furthermore, he aggressively informs you that he has had this problem before, knows what the treatment should be and bids you to get on promptly with giving him some Verapamil or Inderal, which has “always worked in the past.”

He makes it clear that he won't submit to electrical cardioversion because he “had that done once before by some quack and had a headache for a week.” He has a cardiologist whom he rarely sees because “the guy is a jerk.”

His physical exam is normal, apart from a rapid heart rate. His blood pressure is 110/70 mm Hg. Results of his first ECG are shown below (Fig. 1).

For the Answer, see page 114.

Competing interests: None declared.

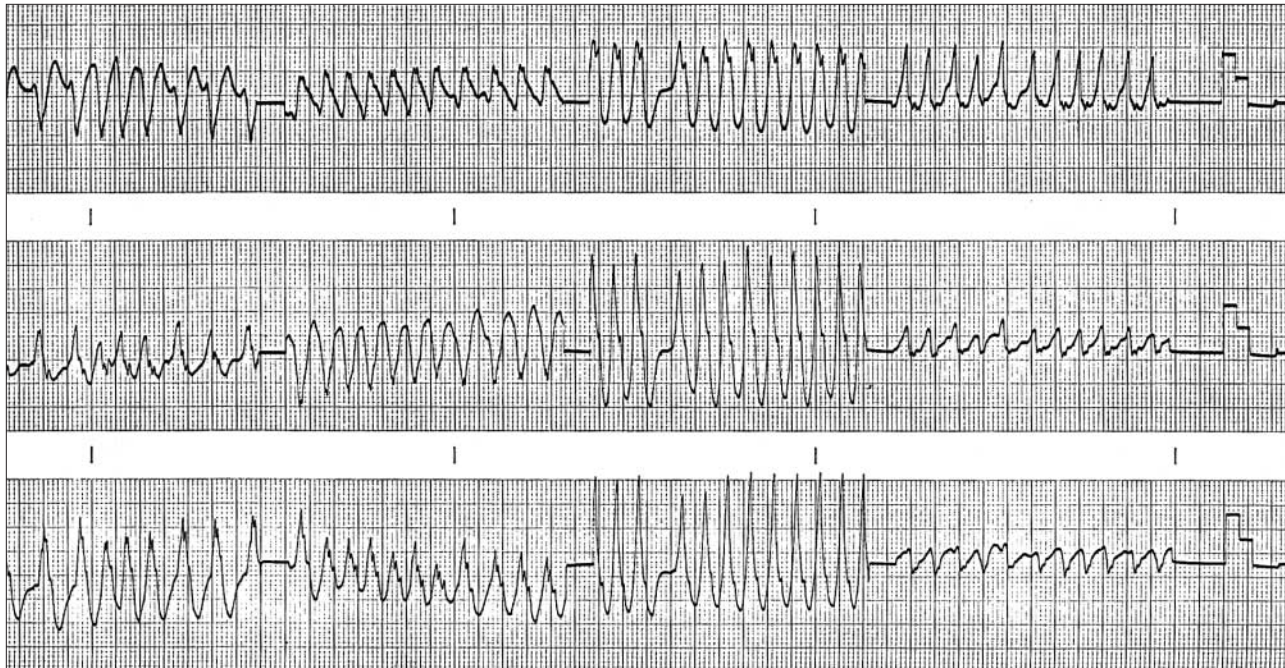


Fig. 1. Results of ECG taken shortly after patient arrived at the emergency department.