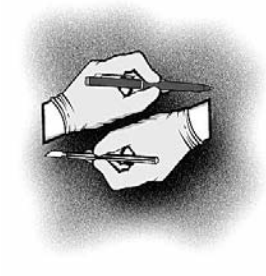

CASE REPORT
OBSERVATIONS DE CAS

Neck injury at a rural emergency department: perils, pitfalls and management considerations

Audra Smallfield, BMSc
Schulich School of Medicine & Dentistry, University of Western Ontario, London, Ont.

Terry Evans, MD, CCFP(EM)
Department of Emergency Medicine, St. Thomas Elgin General Hospital, St. Thomas, Ont.

Munsif Bhimani, MD, MSc, CCFP(EM)
Department of Emergency Medicine, London Health Sciences Centre, Division of Emergency Medicine, Schulich School of Medicine & Dentistry, University of Western Ontario, London, Ont.

Correpondence to: Audra Smallfield; asmallfield2011@meds.uwo.ca

INTRODUCTION

Penetrating neck injuries account for up to 5%–10% of serious traumatic injuries in adults,[1] with an overall mortality rate of about 3%–10%.[2] The optimum management for blunt or penetrating neck injury is challenging, as the spectrum of injury ranges from minor to life-threatening. Rural emergency physicians should be well versed in neck anatomy, diagnostic evaluation of neck injuries and airway salvage techniques, as missed injuries can result in serious morbidity and mortality. We report a case of a patient with pneumocephalus and septic meningitis secondary to a dural tear from a stab wound to the neck.

CASE REPORT

A 32-year-old man presented to the emergency department (ED) at a rural hospital after being stabbed with a beer bottle in a bar fight. His stab wound was a 5-cm laceration to the upper left neck below the ear, just behind the tip of the mastoid process. His temperature was 36.2°C, heart rate was 86 beats/min, blood pressure was 112/69 mm Hg, respiratory rate was 16 breaths/min and oxygen saturation was 97% on room air. He was not actively bleeding from the wound.

The wound was explored and gently irrigated, and no obvious foreign bodies were found. The patient was given an intramuscular tetanus booster dose of 0.5 mL. Once hemostasis was achieved, the wound was sutured and the patient was observed for 2 hours before being discharged.

Several hours later the patient presented to a tertiary care ED with intractable swelling, severe headache and recurrent bleeding. On examination, his temperature was 36.9°C, heart rate was 90 beats/min, blood pressure was 98/65 mm Hg, respiratory rate was 16 breaths/min and oxygen saturation was 97% on room air. He had a Glasgow Coma Scale score of 15 and was maintaining a stable airway. There was a large hematoma at the wound site with active bleeding through the sutures. Neurologic examination revealed some numbness and tingling in the areas of C2–C3, and was otherwise normal.

Computed tomography of the head and neck showed penetration of the dura mater and pneumocephalus (Fig. 1). Magnetic resonance imaging was performed to rule out an epidural cord hematoma. The patient was admitted to

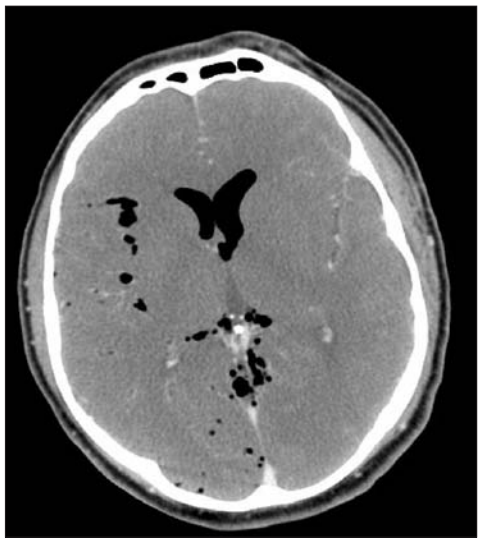

Fig. 1. Computed tomographic scan of the head of a 32-year-old man showing pneumocephalus.

hospital and seen by consultants from ear, nose and throat, and neurosurgery. The wound was explored for vascular injury, the hematoma was drained and the patient was discharged home 1 day later.

During the next couple of days, the patient developed intermittent fevers, headache and neck stiffness and presented again to the tertiary care ED. On examination, he was afebrile with a temperature of 37.0°C and his other vitals signs were stable. His neurologic examination was normal. He complained of some pain with neck flexion and a diffuse headache.

A collection of fluid near the wound site was aspirated and determined to be cerebrospinal fluid (CSF). The patient was admitted for intravenous antibiotics after a presumptive diagnosis of meningitis, pending a lumbar puncture to confirm. The patient received intravenous cefotaxime and vancomycin and was discharged home with a peripherally inserted central catheter line for continuation of antibiotic treatment.

The patient was seen at the trauma clinic of the tertiary care centre for follow-up 2 weeks later. At that time, his headaches had improved, his pain was well controlled and he had regained full range of motion in his neck. Results of blood work were normal, and the incision site was healing well.

DISCUSSION

Penetrating neck injuries, defined by platysma violation, account for up to 5%–10% of traumatic injuries in the United States, but are less commonly seen in Canada.[3] These are particularly challenging injuries to treat because of the complex anatomy of the neck, with vital structures in close proximity to one another. The anatomic classification designed by Roon and Christensen[4] is widely accepted as a means of guiding physicians in the management of penetrating neck injuries. This classification divides the anterior neck into 3 zones as follows:

- zone I: base of the neck; extends from the sternal notch and clavicles to cricoid cartilage
- zone II: midneck; area between cricoid cartilage and angle of mandible
- zone III: upper neck; angle of mandible to base of skull

Zone II is the most commonly injured area in penetrating neck injuries, followed by zones III and I.[5] However, injuries to zone I are associated with the highest mortality because of the vascular injuries frequently sustained in injuries to this area.[6]

The neck can also be divided into anterior and posterior triangles. The anterior triangle is bordered anteriorly by the midline and posteriorly by the sternocleidomastoid muscle. The borders of the posterior triangle are defined by the sternocleidomastoid muscle anteriorly, the clavicle inferiorly and the anterior part of the trapezius muscle posteriorly. Our patient's injury was a posterior triangle injury, which is the least common location for a penetrating neck injury.[5]

Stab wounds to the neck account for 40% of all penetrating neck injuries and are usually low-velocity injuries compared with other mechanisms of penetrating neck injury, such as gunshot wounds.[7] The leading cause of death is exsanguina-

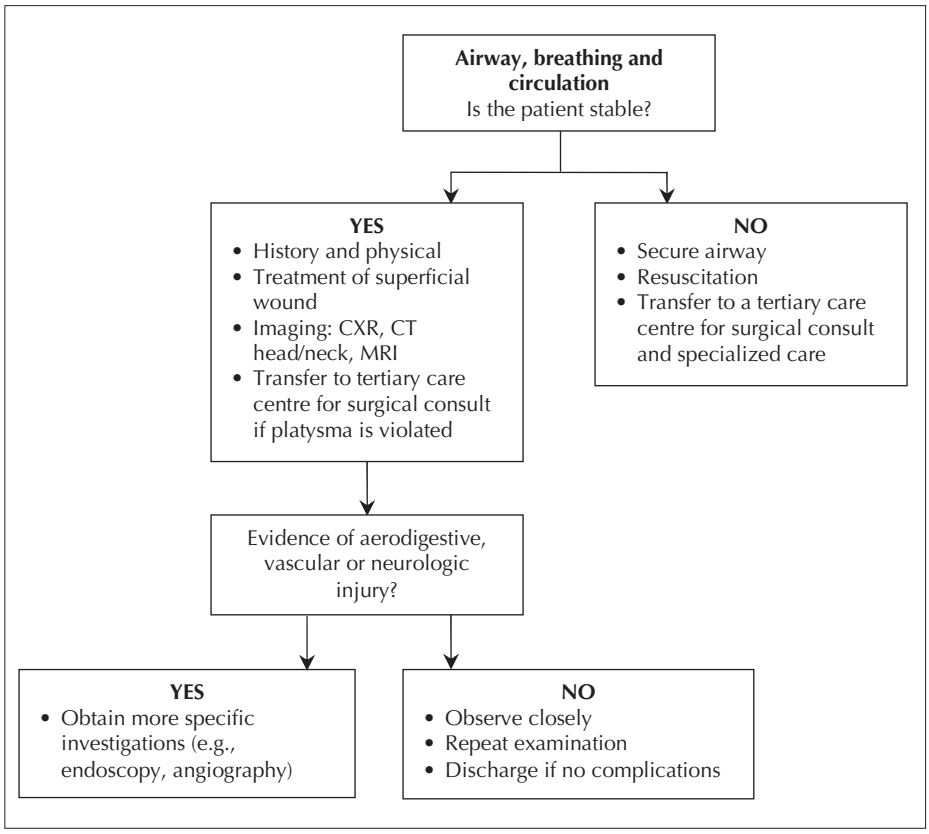

Fig. 2. Management algorithm for neck injuries. In the case of our patient, this approach would suggest early imaging and transfer to a tertiary care centre for surgical consultation. CT = computed tomography; CXR = chest radiography; MRI = magnetic resonance imaging. Modified, with permission, from Uptodate.[15]

tion due to injury of a major vessel, most often the carotid artery.[6] Although our patient avoided damage to any major vessels, pneumocephalus and meningitis developed.

Pneumocephalus is defined as the presence of air in the intracranial cavity and is most often caused by head injury, although it is seen in only 1% of patients with head injury.[8] Stab wounds to the neck represent a rare cause of this finding as only 4 cases have been reported to date (3 in adults and 1 in a child).[9–12] There are 2 theories as to how pneumocephalus develops.[8,11,13] One is that penetration into the subarachnoid space causes a CSF leak, which subsequently creates a negative pressure gradient, allowing air into the intracranial cavity. The second theory is that a dural tear creates a ball-valve effect in that any air forced into the intracranial cavity by coughing or sneezing becomes trapped. Our patient's injury can be explained by the first theory, as the beer bottle that created the stab wound penetrated the subarachnoid space and resulted in a CSF leak that eventually developed into a meningocele. Pneumocephalus can present immediately after the injury or several days later. This was likely the main reason for our patient's presenting headache, although nausea and vomiting may also be present with pneumocephalus.[12] Traumatic tension pneumocephalus can result in rapid clinical deterioration due to increasing intracranial pressure.[14]

Meningitis is an infectious complication seen in 25% of patients with penetrating neck injury involving a tear in the dura.[14] Penetration of the dura by a contaminated object (in this case, a beer bottle) leaves the patient vulnerable to infection of the meninges and CSF. Our patient presented with nuchal rigidity and severe headache several days after the injury that resulted in a dural tear. The absence of fever made this presentation slightly atypical; however, a high index of suspicion lead to the patient's urgent admission for intravenous antibiotics and his quick recovery.

Figure 2 presents a management approach to treatment of neck injuries.[15] This approach emphasizes that early imaging and surgical consultation in relatively stable patients can reveal many of the complications associated with an injury to an area with such complex anatomy.

CONCLUSION

Penetrating injuries to the posterior neck require thorough evaluation, and one must consider that stab wounds to the upper neck may lead to intracranial lesions such as pneumocephalus. Although head injuries still account for the majority of cases of pneumocephalus, stab wounds to the neck are an alternate etiology. Penetrating neck injuries that puncture the dura could also lead to life-threatening meningeal infections. This case stresses the importance of a low threshold for referral to a tertiary care centre for prompt diagnostic imaging and surgical consultation in penetrating neck injuries, so as to recognize clinically important complications, such as pneumocephalus and meningitis.

Competing interests: None declared.

REFERENCES

1. Demetriades D, Skalkides J, Sofianos C, et al. Carotid artery injuries: experience with 124 cases. *J Trauma* 1989;29:91-4.
2. Bell RB, Osborn T, Dierks EJ, et al. Management of penetrating neck injuries: a new paradigm for civilian trauma. *J Oral Maxillofac Surg* 2007;65:691-705.
3. Nason RW, Assuras GN, Gray PR, et al. Penetrating neck injuries: analysis of experience from a Canadian trauma centre. *Can J Surg* 2001;44:122-6.
4. Roon AJ, Christensen N. Evaluation and treatment of penetrating cervical injuries. *J Trauma* 1979;19:391-7.
5. Wood J, Fabian TC, Mangiante EC. Penetrating neck injuries: recommendations for selective management. *J Trauma* 1989;29:602-5.
6. Thal ER, Meyer DM. Penetrating neck trauma. *Curr Probl Surg* 1992;29:1-56.
7. Brywczynski JJ, Barrett TW, Lyon JA, et al. Management of penetrating neck injury in the emergency department: a structured literature review. *Emerg Med J* 2008;25:711-5.
8. Waring GO III, Flanagan JC. Pneumocephalus. A sign of intracranial involvement in orbital fracture. *Arch Ophthalmol* 1975;93:847-50.
9. Uppot RN, Gheyi VK, Gould SW, et al. Pneumocephalus and Brown-Séquard's Neurologic injury caused by a stab wound to the neck. *AJR Am J Roentgenol* 1999;173:1504.
10. Kabuto M, Tsuji T, Sasaki H, et al. Traumatic pneumocephalus caused by a stab wound to the neck. *Rinsho Hoshasen* 1988;33:499-502.
11. Naseem M, Hood JD, Devasthali R. Traumatic pneumocephalus caused by stab wound to the neck. *AJNR Am J Neuroradiol* 1986;7:174-5.
12. Bunc G, Roskar Z, Vorsic M. Pneumocephalus secondary to a neck stab wound without neurologic injury in a 13-year-old girl. *Pediatr Neurosurg* 2001;34:239-41.
13. Lewin W. Cerebrospinal fluid rhinorrhea in nonmissile head injuries. *Clin Neurosurg* 1964;12:237-52.
14. Detorakis ET, Drositis I, Drakonaki EE, et al. Pneumocephalus and presumed meningitis following inconspicuous penetrating periocular trauma. *Acta Ophthalmol Scand* 2004;82:603-5.
15. Newton, K. *Penetrating neck injuries*. Waltham (MA): UptoDate. Available: www.uptodateonline.com/patients/content/topic.do?topicKey=~Dttj_.76dVME6m&selectedTitle=1%7E7&source=search_result (accessed 2009 Apr. 13).